



## Small bowel incarceration as a complication of port site drainage following laparoscopic hysterectomy

### Ukleštenje tankog creva kao komplikacija drenaže nakon laparoskopske histerektomije

Saša Ljuština\*, Radmila Sparić\*, Sanja Novaković†, Snežana Buzadžić\*

\*Clinic for Gynecology and Obstetrics, Clinical Center of Serbia, Belgrade, Serbia;

†Department for Gynecology, Military Medical Academy, Belgrade, Serbia

#### Abstract

**Introduction.** Indication for surgical drainage may be prophylactic or therapeutic. However, surgical drains may cause complications. These complications can arise either following laparoscopic or open surgery. One of the rare complications resulting from drainage includes herniation of abdominal viscera at the drain site. The most common herniated abdominal organ is the small bowel. **Case report.** A 75-year-old woman underwent laparoscopic hysterectomy for atypical endometrial hyperplasia. After the operation, she developed small bowel herniation in the abdominal wall at the drain site, which was confirmed by multislice computed tomography. The patient underwent emergency relaparotomy that identified drain site incarceration of an ileal loop. Following resection of the incarcerated bowel, her postoperative recovery was uneventful. **Conclusion.** This case presents rare causative mechanism of intestinal obstruction. The possible occurrence of hernias following surgical drainage must be kept in mind.

#### Key words:

drainage; hysterectomy; laparoscopy; postoperative period; hernia; intestine, small; abdominal wall.

#### Apstrakt

**Uvod.** Indikacija za hiruršku drenažu može biti profilaktička ili terapijska. Međutim, hirurška drenaža može imati komplikacije, koje mogu pratiti bilo laparoskopsku ili otvorenu hirurgiju. Jedna od retkih komplikacija drenaže je visceralna hernijacija na defektu trbušnog zida nastalog stavljanjem drena. Među abdominalnim organima, tanko crevo najčešće podleže hernijaciji. **Prikaz bolesnika.** Bolesnici, staroj 75 godina, zbog atipične endometrijalne hiperplazije urađena je laparoskopska histerektomija. Nakon operacije došlo je do hernijacije tankog creva u zidu abdomena na mestu drena, što je potvrđeno kompjuterizovanom tomografijom abdomena. Kada je identifikovana inkarceracija vijuge tankog creva na mestu drena urađena je relaparotomija. Postoperativni tok protekao je uredno. **Zaključak.** Prikazan je redak uzročni mehanizam intestinalne opstrukcije. Mogućnost nastanka hernija nakon postoperativne drenaže mora se imati na umu.

#### Ključne reči:

drenaža; histerektomija; laparoskopija; postoperativni period; hernija; crevo, tanko; abdomen, zid.

#### Introduction

An indication for surgical drainage may be prophylactic (preventing fluid accumulation or detecting anastomotic leakage) or therapeutic (to evacuate existing collection of fluid)<sup>1,2</sup>. Although surgical drainage is useful, it can also cause serious complications such as severe tissue reactions, leaving behind a foreign body, hemorrhage, leakage from bowel anastomoses and the induction of infection, while drain site visceral herniation is a rare complication<sup>1,3</sup>. Commonly these hernias occur several months to several years following surgery. The most common herniated abdominal organs are small bowel

loop and appendix, but unusual contents of drain site hernia such as Fallopian tube or gallbladder are also described<sup>1-4</sup>.

The main reason for postoperative bowel obstruction is adhesion formation, but it can also arise because of an incision hernia<sup>5</sup>. These hernias may follow both laparoscopic and open surgery, on the incision, drain or port site. Infrequently, they appear in the immediate postoperative period, following drain removal and presenting as a surgical emergency due to intestinal obstruction.

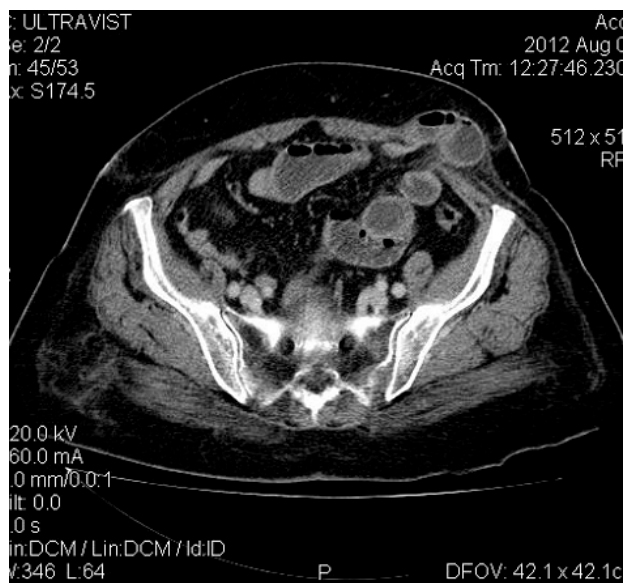
The aim of this report was to raise awareness of this complication, as too liberal use of prophylactic drainage following laparoscopic surgery can jeopardize the basic idea

of minimally invasive surgery, causing a complication that requires an additional surgical procedure.

### Case report

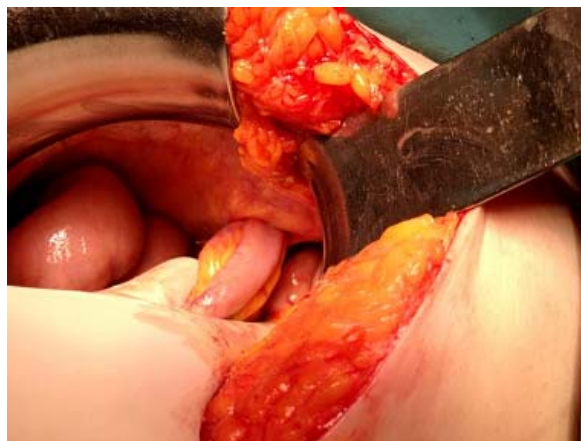A 75-year-old woman was referred to our hospital for hysterectomy due to atypical endometrial hyperplasia. The patient's medical history revealed cardiovascular disease, as well as breast cancer. The patient underwent left radical mastectomy two years before, and was treated with tamoxifen.

A total laparoscopic hysterectomy and bilateral salpingo-oophorectomy were performed without difficulties. There were no pathological findings within peritoneal cavity during the operation. An open silicone 5-mm soft drain was placed in the abdominal cavity through the left lateral laparoscopic port for prophylactic reasons. The drain-tube was taken out on the second postoperative day, without any registered complications and the patient had regular bowel sounds. The patient had an uneventful postoperative recovery until the fourth postoperative day, when she suffered vomiting and abdominal pain. On the fifth postoperative day a bulging, nonductible, tender mass with 20 × 30 mm diameter, protruding just above the drain site incision was detected. The ultrasonography revealed a mass with 23 × 32 × 20 mm and low echogenicity located in the left abdominal wall. The diagnosis of abdominal wall hematoma was considered. There were no clear signs of acute abdomen. Radiographic examination did not reveal the presence of air – fluid levels. The patient continued vomiting, bowel sounds became absent and repeated radiographic examination on the sixth postoperative day showed intestinal air – fluid levels. The surgeon was consulted and he ordered abdominal multislice computed tomography. Computed tomography of the abdomen showed herniated loop of the small bowel in the left lateral abdominal wall (Figure 1). The patient underwent emergency repeated laparotomy that identified drain site in-

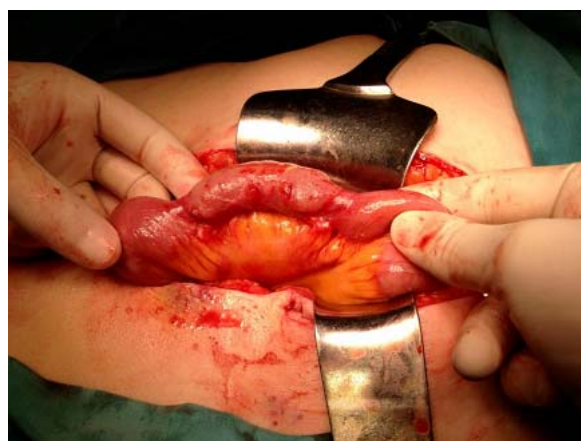

**Fig. 1** – Multislice computed tomography image of the abdomen shows a herniated loop of the small bowel in the left lateral abdominal wall.

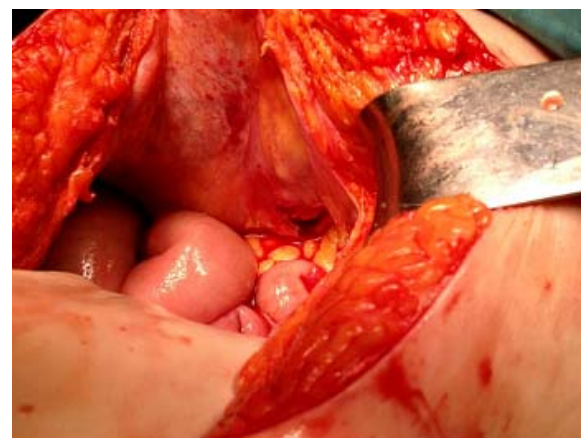carceration of an ileal loop (Figure 2). The wall of herniated intestinal loop was damaged because of multi-day incarceration (Figure 3). During the surgery, a residual peritoneal opening at drain site was visible (Figure 4). A 5 cm long small-bowel segment was resected and end-to-end anastomosis performed. The abdominal wall defect was sutured. The patient's further recovery was excellent, and the patient was discharged 13 days after the second surgery. At present, 13 months after the operation, the patient did not experience any recurrence of hernia.



**Fig. 2** – Drain site incarceration of an ileal loop.



**Fig. 3** – Herniated ileal loop with altered wall morphology as a consequence of multi-day incarceration.



**Fig. 4** – Residual peritoneal opening at abdominal drain site.

## Discussion

There is a debate considering drainage in surgical practice. Drainage following abdominal surgery is used to detect intra-abdominal fluid, such as inflammatory or hemorrhagic, or content of anastomotic leak<sup>1,2</sup>. On the other hand, complications of drainage described in the literature are numerous<sup>1,3</sup>. Therefore some investigators advocate that indications for prophylactic drainage should be minimized, and suggest not to use drains in uncomplicated operations<sup>6</sup>. However, therapeutic drain usage is very important especially for surgical operations involving major bacterial contamination<sup>2</sup>.

Port site hernias are uncommon complication of laparoscopic surgery, causing significant morbidity. Review of the literature revealed numerous reports of incisional hernias on trocar port sites after laparoscopy<sup>5-9</sup>. They are promoted by pneumoperitoneum during this kind of surgery. There are also reports about incisional hernias following similar defects of abdominal wall after drainage procedures in open surgery<sup>1,10,11</sup>. Most of the reported cases refer to the drains with diameter larger than 10 mm<sup>11</sup>. Predisposing factors for incisional hernias are thinness and malnutrition, obesity, pre-existing morbidity such as diabetes mellitus, corticosteroids therapy, increased intraabdominal pressure (vomiting, coughing), advanced age, prolonged surgery and wound infection<sup>12</sup>. The literature provides several recommendations considering drainage: asymmetrical method of drain inser-

tion which causes peritoneal stretching, gradual removal of the drain, drain site inspection after drain removal, usage of smaller drains in elderly and thin patients (diameter less than 10 mm), purse string closure of fascia defect after removing drains whenever the defect measures 10 mm or more in size<sup>3,7,11</sup>.

Herniation rarely occurs with drains smaller than 10 mm, as in our patient. The most probable mechanism in the presented case was manipulation at the port site causing the enlargement of the abdominal wall defect and drain insertion through the port site. Nevertheless, we cannot rule out the possibility of pulling intestinal loop into the abdominal wall defect during drain removal. General weakness of the abdominal wall muscle caused by advanced age probably facilitated this complication in the presented patient.

## Conclusion

Drains should be used sparingly and careful insertion and management is necessary. One must never forget that drain placement creates an iatrogenic defect of the abdominal wall located at the wound incision, and that these defects are large enough to create a risk of hernia formation. It is important to make a diagnosis of this potential complication in time because it will significantly reduce further morbidity. Therefore, the possible occurrence of hernias following removal of a drainage tube must be kept in mind.

## R E F E R E N C E S

1. Falidas E, Mathionlakis S, Vlachos K, Pavlakis E, Villias C. Strangulated intestinal hernia through a drain site. *Int J Surg Case Rep* 2012; 3(1): 1-2.
2. Vedat B, Açıöz S, Çetin K. Evisceration of gallbladder at the site of a Pezzer drain: a case report. *Cases J* 2009; 2(1): 8601.
3. Sharma L, Singh A, Bhaskaran S, Radhika AG, Radhakrishnan G. Fallopian tube herniation: an unusual complication of surgical drain. *Case Rep Obstet Gynecol* 2012; 2012: 194350.
4. Duraker N, Büyüksakik K, Helvacioğlu Y. Drain site evisceration of the appendix: report of a case. *Surg Today* 1997; 27(7): 651-2.
5. Kadija S, Sparić R, Žižić V, Stefanović A. Drainage as a rare cause of intestinal incarceration. *Srp Arh Celok Lek* 2005; 133(7-8): 370-1. (Serbian)
6. Gurusamy KS, Samraj K, Mullerat P, Davidson DR. Routine abdominal drainage for uncomplicated laparoscopic cholecystectomy. *Cochrane Database Syst Rev* 2007; 4: CD006004.
7. Komuta K, Haraguchi M, Inoue K, Furui J, Kanematsu T. Herniation of the small bowel through the port site following removal of drains during laparoscopic surgery. *Dig Surg* 2000; 17(5): 544-6.
8. Yamamoto M, Minikel L, Zaritsky E. Laparoscopic 5-mm trocar site herniation and literature review. *JSL* 2011;15(1): 122-6.
9. Poon C, Leong HT. Abdominal drain causing early small bowel obstruction after laparoscopic colectomy. *JSL* 2009; 13(4): 625-7.
10. Makama JG, Ahmed A, Ukwanya Y, Mohammed I. Drain site hernia in an adult: a case report. *West Afr J Med* 2010; 29(6): 429-31.
11. Rehman JM, Seow CS, O'Dwyer PJ. A case of a Spigelian hernia at an unusually high anatomical location. *J R Coll Surg Edinb* 2000; 45(3): 196-7.
12. Lob A, Jones PA. Evisceration and other complications of abdominal drains. *Postgrad Med J* 1991; 67(789): 687-8.

Received on September 23, 2013.

Accepted on October 16, 2013.